

# **A Computed Tomographic Study of Canal Variations in Maxillary & Mandibular first Premolar Teeth in Jaipur Population – An *in vitro* Study.**

**Deepak Sharma, Meetu Mathur**

Department of Conservative Dentistry & Endodontics, Jaipur Dental College, Jaipur.

## **Abstract:**

The present study was carried out to observe root canal variations in maxillary and mandibular first premolar teeth in the local population using spiral computed tomography. Sixty, each of well formed maxillary and mandibular first premolar teeth without any carious lesions were used in this study. They were placed in 5% sodium hypochlorite solution for 30 minutes for the removal of organic debris. They were then stored in normal saline till further experiment was carried out. Each tooth was scanned with a slice thickness of 0.625 mm. Data collected was used to reconstruct the scanned teeth three dimensionally. The configuration seen in longitudinal and transverse sections was used to classify the canal anatomy according to Vertucci's classification.

**Key Words:** First premolar, Mandibular, Maxillary, Vertucci's classification, Spiral computed tomography.

---

## **Introduction:**

Anatomical complexities of the root canal system has been long established. A root with a graceful tapering canal and a single foramen is the exception rather than the rule. Any attempt to perform endodontic therapy must be preceded with a thorough understanding of the anatomy of both the pulp chamber and the root canal system (Krasner & Rankow, 2004).

Anatomical variability of the teeth is often a complicating factor in root canal treatment and many different methods have been used to investigate tooth morphology (Mikrogeorgis et al, 1999). These methods include decalcification of the teeth and dye injection (Vertucci, 1984). The various dyes used are India Ink (Gulabivala et al, 2001), hematoxylin dye etc. Radiographic studies *in vitro* (Gonzalez & Gonzalez, 2003), sectioning of teeth (Weine et al, 1999) have been used to study the anatomy of the pulp floor.

However, except the radiographic technique, all these are *in vitro* techniques and cannot be used clinically. Furthermore, they do not provide the ability to study the external and internal anatomy of teeth three-dimensionally (Mikrogeorgis et al, 1999).

Current literature shows that where atypical anatomy is suspected, in addition to the conventional radiograph, modern radiographic techniques like helical or spiral computed tomography are being used for a proper diagnosis.

Tachibana & Matsumoto (1990) were the first to study the applicability of computerized tomography in endodontics.

Computed tomography scans cause no geometric distortions on magnification while determining the canal morphology of teeth (Vannier et al, 1997).

Spiral computed tomography (SCT) has gained popularity in the study of hard tissues (Chandra et al, 2009). The successful use of SCT in dentistry was reported by Robinson et al (2002). Sponchiado et al(2006) confirmed the variations in the root canal anatomy using SCT. The advantage of SCT is that it offers a non-invasive reproducible technique for 3-dimensional assessment of root canal system and aids the clinician to visualize the internal anatomy precisely.

Therefore, it was decided to study the variations in canal configurations of maxillary and mandibular first premolar teeth using spiral computed tomography.

## **Material and Methods:**

Sixty each of non-carious maxillary & mandibular first premolars were collected and used for this study. The teeth were extracted in the Department of Oral and maxillo-facial Surgery, Jaipur Dental College & Hospital, Jaipur, due to trauma, periodontal disease or for orthodontic reasons. The teeth were collected without consideration of age, sex and religion. The extracted teeth were thoroughly washed and were cleaned to remove blood, saliva or any debris. They were then placed in 5% sodium hypochlorite solution for thirty minutes for the removal of organic debris

---

**Corresponding Author:** Dr. Meetu Mathur, S-3, Shyam Nagar, Main Ajmer Road, Near Vipul Motors, Jaipur – 302019 (Rajasthan)  
**Phone No.:** 09414078360  
**E-mail :** mathur.meetu@gmail.com

from the surface. Calculus, if present, was removed using ultrasonic scaler. The cleaned samples were then stored in normal saline till further experiment was carried out.

**Preparation of specimens :**

The specimens were randomly divided into fifteen batches of four teeth each for maxillary and mandibular teeth. The teeth of each batch were mounted on a platform made with the help of modelling wax (Fig. I). The teeth were subjected to high quality computed tomography (G.E. Light Speed Pro) scanner which acquires 40 slices per second (Fig. II). Each tooth was viewed in longitudinal as well as in transverse sections. The transverse sections were studied at the cervical, middle and apical third.

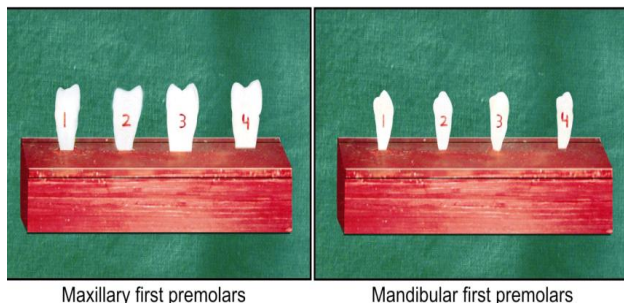


Fig. I: Mounted on a platform made with the help of modelling wax.

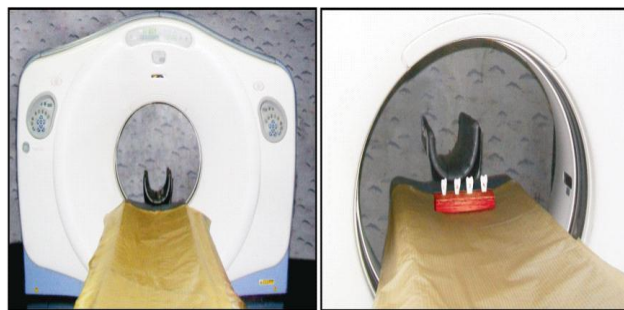

Fig. II: Teeth subjected to high quality computed Tomography (G.E. Light Speed Pro) Scanner.

Each tooth was scanned from crown to anatomical apex at a high resolution with a slice thickness of 0.625 mm. Data collected was then used to reconstruct the scanned teeth three dimensionally. This was done on a separate workstation using AW 4.2 GE (Reuben et al, 2008) software. The configuration seen in the longitudinal sections and transverse sections of the maxillary teeth (Fig. III) and mandibular teeth (Fig. IV) were used to classify the canal anatomy according to Vertucci's classification.

The results were statistically analyzed by Chi-square test using statistical package for social sciences (SPSS) software.

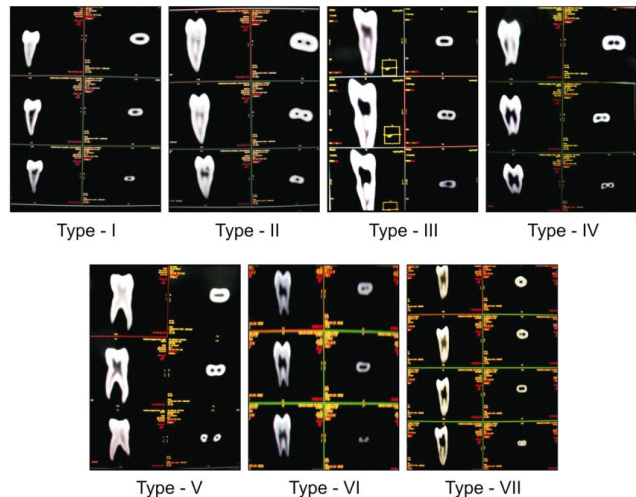


Fig. III: Showing the types of configurations seen in longitudinal and transverse sections in maxillary first premolar teeth according to Vertucci's classification.

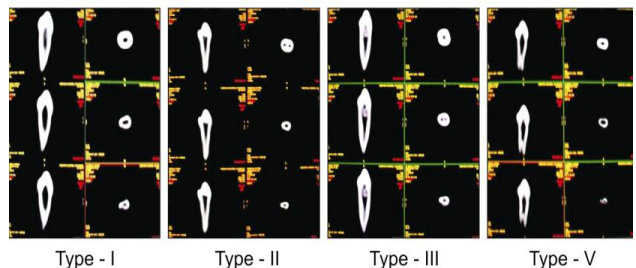


Fig. IV: Showing the types of configurations seen in longitudinal and transverse sections in mandibular first premolar teeth according to Vertucci's classification.

**Results:**

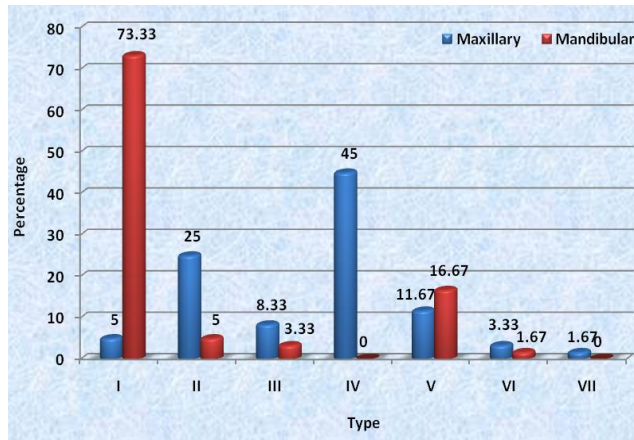
The different types of root canal systems found in 60 maxillary and 60 mandibular first premolars are depicted in Table I & Fig. I. It was observed that the canal anatomy of maxillary first premolars varied considerably.

Table I: Distribution according to type of canal configuration and type of teeth.

Type	Maxillary 1 <sup>st</sup> premolar (n=60)		Mandibular 1 <sup>st</sup> premolar (n=60)		$\chi^2$	d.f.	p-value	Significance
	No.	%	No.	%				
I	3	5.00	44	73.33	27.980	1	<.001	HS
II	15	25.00	3	5.00	7.908	1	<.01	Sig
III	5	8.33	2	3.33	0.607	1	>.05	NS
IV	27	45.00	0	0.00	-	-	-	-
V	7	11.67	10	16.67	0.617	1	>.05	NS
VI	2	3.33	1	1.67	0.000	1	>.05	NS
VII	1	1.67	0	0.00	-	-	-	-

HS: Highly significant, NS: Non Significant, Sig: Significant

Fig. I: Showing the canal configurations in maxillary and mandibular first premolars.



Type I configuration was found in 3 teeth (5%) and 44 teeth (73.33%) in maxillary & mandibular premolar respectively. Value of  $\chi^2$  (Chi square) was 27.980 with the degree of freedom 1 (p value < 0.001) which is highly significant.

Type II canal configuration was found in 15 (25%) maxillary premolars and 3 (5%) mandibular premolars. The p value was <0.01 which is significant.

Type III canal configuration was observed in 5 (8.33%) maxillary and 2 (3.33%) mandibular premolars. The difference was insignificant (p > 0.05). Type IV canal configuration was found only in maxillary premolars (27 teeth;45%).

Type V configuration was found in 7 (11.67%) maxillary and 10 (16.67%) mandibular premolars. In maxillary premolars type VI configuration was seen in 2 (3.33%) and 1 (1.67%) in mandibular premolars. In both type V and type VI configuration the difference was insignificant.

Type VII configuration was only found in 1 (1.67%) maxillary first premolar.

The distribution according to the number of canals at the apex and type of teeth are presented in Table II & Fig. II. In maxillary first premolars 1 canal was found at the apex in 38.33% teeth and 2 canals in 61.67% of teeth, while in mandibular first premolars 1 canal was found at the apex in 81.67% teeth and 2 canals in 18.33% teeth. The difference was statistically highly significant (p<0.001). Therefore, it can be said that there is a significant association between the number of canals found at the apex and the type of teeth.

The distribution according to the number of orifices at the floor of the pulp chamber and type of

teeth are shown in Table III & Graph III. In maxillary teeth 26.67% had 1 orifice and 73.33% had 2 orifices at the floor of the pulp chamber. Whereas, in mandibular first premolars 93.33% had 1 orifice and 6.67% had 2 orifices at the floor of the pulp chamber. The difference was statistically highly significant (p<0.001).

Table II: Distribution according to number of canals at apex and type of teeth:

No. of canals at apex	Maxillary 1 <sup>st</sup> premolars		Mandibular 1 <sup>st</sup> premolars	
	No. of teeth	%	No. of teeth	%
1	23	38.33	49	81.67
2	37	61.67	11	18.33

$\chi^2 = 23.472$  d.f.=1 p < .001 HS

Fig. II: Showing the percentage of canals at the apex in maxillary and mandibular first premolars.

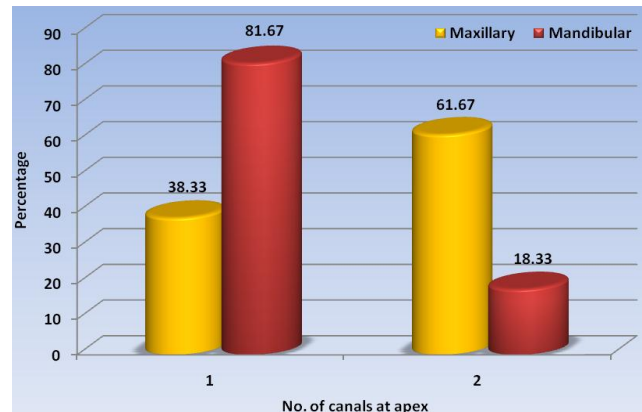


Table III: Showing the percentage of number of orifices present at the floor to pulp chamber in maxillary and mandibular first premolars.

No. of orifices at the floor of the pulp chamber	Maxillary 1 <sup>st</sup> premolars		Mandibular 1 <sup>st</sup> premolars	
	No. of teeth	%	No. of teeth	%
1	16	26.67	56	93.33
2	44	73.33	4	6.67

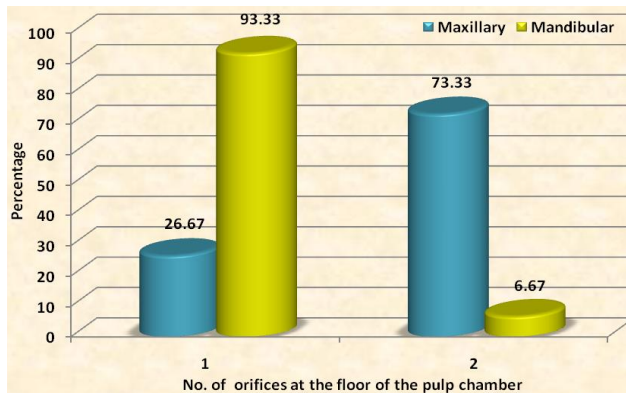
$\chi^2 = 52.82$  d.f.=1 p < .001 HS

**Discussion:**

An accurate knowledge of the root canal morphology and its anatomical variations is required for successful root canal treatment. The variability of

root canal morphology is a challenge to both endodontic diagnosis and treatment. The identification of the internal morphology as precisely as possible is the primary step in root canal treatment. A complex root canal anatomy requires modifications in the access cavity (Rekha et al, 2005).

Fig. III: Showing the percentage of number of orifices present at the floor of pulp chamber in maxillary and mandibular first premolars.



Krasner & Rankow (2004) made a rationale approach to study the relationship of the pulp chamber to the clinical crown and pulp chamber floor. Their observations put forth in the form of laws are valuable aids to the Clinician in searching for elusive canals.

Various studies have reported variations in canal configurations in maxillary first premolars (Pineda & Kuttler, 1972; Green, 1973, Vertucci, 1984, Kartal et al, 1998) and mandibular first premolars (Baisden et al, 1992; Cleghorn et al, 2007; Velmurugan & Sandhya, 2009, Khedmat et al, 2010).

It is apparent from the literature that there is a divergence of opinion concerning the anatomical configuration of the pulp cavity of the maxillary and mandibular first premolar teeth. Vertucci in 1984 in his extensive study on root canal anatomy of human permanent teeth reported that maxillary first premolar was the only tooth which had all the eight types of canal configurations. He also reported that type-IV canal configuration was present in 1.5% of cases in mandibular first premolars. This is in variation with the present study in which type IV was not found. Type VII configurations was not found in the present study in mandibular first premolars which is in agreement with his study.

Pineda & Kuttler (1972) studied the normal root canal anatomy and its variations in both mesiodistal and buccolingual directions and found that in maxillary premolars 50.1% had one canal and 49.4% of teeth

had two canals at the apex. While in mandibular first premolars 74.2% had one canal and 24.9% had two canals at apex.

This is in variation with the study of Green (1973). He reported 1 canal in 8% and 2 canals at apex in 92% of maxillary first premolars. While in mandibular first premolars he reported 1 canal in 86% teeth and 2 canals at apex in 14% teeth.

Baisden (1992) reported that 76% of mandibular first premolars demonstrated type-I and 24% had type IV canal configuration.

Iyer et al (2006) in their study reported that mandibular premolars exhibit a high degree of complex anatomy with fine ribbon shaped canal systems which are difficult to access, clean and obturate. The study was done using radiovisiography in different angulations to highlight the anatomical aberrations (Cleghorn et al, 2008; Moayed i & Lata A, 2004).

According to Segovic et al (2004) the incidence of maxillary first premolars with 3 roots, 3 canals and 3 foramina is about 4-6%.

Sandhya et al (2010) conducted a study to assess the root canal morphology of mandibular first premolars in the Indian population using spiral computed tomography. The study showed that 80% of the teeth had a single canal, 11% had 2 canals and C-shaped canals were found in 2% of the teeth.

In the present study, root canal configurations were clearly visualized in 3-dimensions by using spiral computed tomography. It can therefore, be used as an adjunct to existing diagnostic aid especially in those areas where conventional radiographic methods give a complex picture. This information gained prior to the initiation of therapy will greatly help in successful subsequent treatment.

Since in India, there are different ethnic groups present, further studies of this nature are suggested to look for the variations in tooth morphology in different regions and reduce the incidence of failure by using advanced imaging systems.

### Bibliography:

1. Baisden MK, Kulild JC, Weller RN: Root canal configuration of the Mandibular First Premolar. *Journal of Endodontics*, 1992; 18(10): 505-508.
2. Cleghorn BM, Christie WH, Dong CC: The root and root canal morphology of the human mandibular first premolar : a literature review. *Journal of Endodontics*, 2007; 33(5) : 509-516.
3. Cleghorn BM, Christie WH, Dong CCS: Anomalous

- mandibular premolars: a mandibular first premolar with three roots and mandibular second premolar with a C-shaped canal system. *International Endodontic Journal*, 2008; 41(11):1005-1014.
4. Chandra SS, Rajasekaran M, Shankar P, Indira R: Endodontic management of a mandibular first molar with three distal canals confirmed with the aid of spiral computerized tomography. *Oral Surgery, Oral Medicine, Oral Pathology Oral Radiology & Endodontics*, 2009; 108(4): e77-e81.
  5. Green D: Double canals in single roots. *Oral Surgery, Oral Medicine & Oral Pathology*, 1973; 35(5): 689-696.
  6. Gonzalez-Plata RR, Gonzalez-Plata E W: Conventional and surgical treatment of a Two-rooted Maxillary Central Incisor. *Journal of Endodontics*, 2003; 29(6): 422-424.
  7. Gulabivala K, Aung TH, Alavi A, Ng YL: Root and canal morphology of Burmese mandibular molars. *International Endodontic Journal*, 2001; 34(5): 359-370.
  8. Iyer VH, Indira R, Ramachandran S, Srinivasan MR: Anatomical variations of mandibular premolars in Chennai population. *Indian Journal of Dental Research*, 2006; 17(1): 7-10.
  9. Kartal N, Ozelcik B, Cimilli H: Root canal morphology of Maxillary Premolars. *Journal of Endodontics*, 1998; 24(6) : 417-419.
  10. Khedmat S, Assadian H, Saravani AA: Root Canal Morphology of the Mandibular First Premolars in an Iranian Population Using Cross-sections and Radiography. *Journal of Endodontics*, 2010; 36(2): 214-217.
  11. Krasner P, Rankow HJ: Anatomy of the pulp-chamber floor. *Journal of Endodontics*, 2004; 30(1): 5-16.
  12. Mikrogeorgis G, Lyroudia KL, Nikopoulos N, Pitas I, Molyvdas I, Lambrianidis TH: 3-D computer aided reconstruction of six teeth with morphological abnormalities. *International Endodontic Journal*, 1999; 32(2): 88-93.
  13. Moayedi S, Lata DA: Mandibular first premolar with three canals. *Endodontology*, 2004; 16: 26-29.
  14. Pineda F, Kuttler Y: Mesiodistal and buccolingual roentgenographic investigation of 7,275 root canals. *Oral Surgery, Oral Medicine & Oral Pathology*, 1972; 33(1): 101-110.
  15. Reuben J, Natanasabapathy V, Kandaswamy D: The Evaluation of Root Canal Morphology of the Mandibular First Molar in an Indian Population Using Spiral Computed Tomography Scan : An *in vitro* study. *Journal of Endodontics*, 2008; 34(2): 212-215.
  16. Rekha SG, Nadig P, Nadig G: Endodontic treatment of a maxillary first premolar with three roots a case report. *Journal of Conservative Dentistry*, 2005; 8(4): 26-29.
  17. Robinson S, Czerny C, Gahleitner A, Bernhart T, Kainberger FM: Dental CT evaluation of mandibular first premolar root configurations and canal variations. *Oral Surgery, Oral Medicine, Oral Pathology, Oral Radiology & Endodontics*, 2002; 93(3): 328-332.
  18. Segovic S, Pavelic B, Jukic S, Anic I: Three Rooted Maxillary First Premolars : Five Clinical Cases. *Acta Stomatologica Croatica*, 2004; 38(4): 379-380.
  19. Sandhya R, Velmurugan N, Kandaswamy D: Assessment of root canal morphology of mandibular first premolars in the Indian population using spiral computed tomography : An *in vitro* study. *Indian Journal of Dental Research*, 2010; 21(2): 169-173.
  20. Sponchiado EC, Ismail HAAQ, Braga MRL, De Carvalho FK, Simoes CACG: Maxillary Central Incisor With Two Root Canals. *Journal of Endodontics*, 2006; 32(10): 1002-1004.
  21. Tachibana H, Matsumoto K: Applicability of X-ray computerized tomography in endodontics. *Dental Traumatology*, 1990; 6(1): 16-20.
  22. Vannier MW, Hildebolt CF, Conover G, Knapp RH, Yokoyama-Crothers Y, Wang G: Three dimensional dental imaging by Spiral CT. *Oral Surgery, Oral Medicine, Oral Pathology, Oral Radiology & Endodontics*, 1997; 84(5): 561-570.
  23. Velmurugan N, Sandhya R: Root canal morphology of mandibular first premolars in an Indian population : a laboratory study. *International Endodontic Journal*, 2009; 42(1): 54-58.
  24. Vertucci FJ: Root canal anatomy of the human permanent teeth. *Oral Surgery, Oral Medicine & Oral Pathology*, 1984; 58(5): 589-599.
  25. Weine FS, Hayami S, Hata G, Toda T: Canal configuration of the mesiobuccal root of the maxillary first molar of a Japanese sub-population. *International Endodontic Journal*, 1999; 32(2): 79-87.